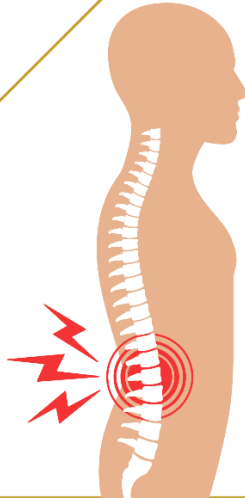




جامعة الإمام عبد الرحمن بن فيصل
IMAM ABDULRAHMAN BIN FAISAL UNIVERSITY

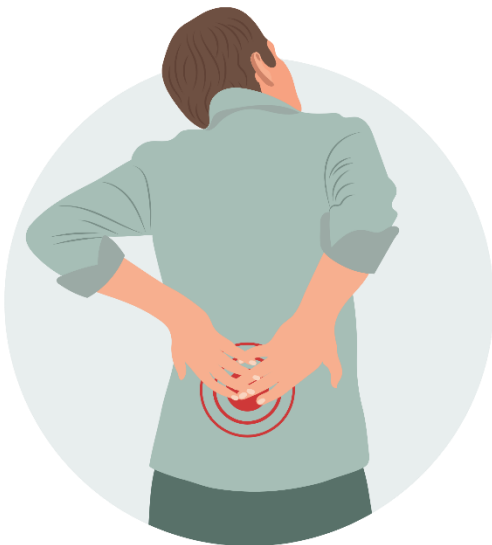مستشفى الملك فهد الجامعي
King Fahad Hospital The University

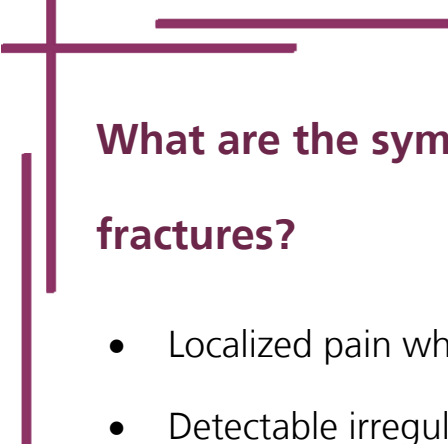
Spinal Trauma and Injuries




What are the vertebral fractures?

- **Trauma:** Such as car accidents, falls, gunshot wounds.
- **Pathological fractures:**
 - Osteoporosis (most common)
 - Malignancy (e.g., bone metastases)
 - Infection (e.g., Pott disease (Tuberculosis), Brucella)





What are the symptoms of vertebral fractures?

- Localized pain when pressure is applied.
 - Detectable irregularity or misalignment in the vertebrae.
 - Weakness or sensations of numbness and tingling.
 - Formation of a hematoma near the spine.
 - Significant anterior compression leading to structural kyphosis.
 - Possible development of additional symptoms, including paralysis, based on complications and associated injuries.
 - Asymptomatic courses are also possible.
- 

What are the vertebral fractures classifications?

✚ Stability of vertebral fractures

The degree of fracture stability is the most important feature of any spinal column injury. Because it will determine the course of treatment:

- **Stable vertebral fracture**
- The spine's structural stability is preserved.
- No neurological deficits are present.
- Typically involves fractures in the anterior column of the spine.
- **Unstable vertebral fracture**
- The spine's structural stability is compromised.

What are the vertebral fractures classifications?

✚ Stability of vertebral fractures

- Continue unstable vertebral fracture
 - The spine may move as two or more independent units, increasing the risk of spinal cord injury.
 - Involves fractures in the mid-column and posterior column of the spine

What is the vertebral fractures diagnosis?

✚ Physical exam

- Comprehensive Neurological Assessment: Includes evaluation of cranial nerves, motor and sensory functions, coordination, and reflexes.
- Rectal Examination: Performed to assess sphincter activation and functionality

What is the vertebral fractures diagnosis?

Radiology

- **Anterior-Posterior and Lateral X-rays:** Used to detect:
 - Presence of bone fragments.
 - Reduction in the height of the vertebral bodies.

- **CT:**

Axial imaging aids in pinpointing the fracture location and evaluating posterior edge stability as well as being used for surgical planning.

- **MRI:**

most sensitive tool for detecting spinal cord lesions and ligamentous injury.

What is conservative treatment for stable fractures?

- Pain medication
- Physical therapy
- External bracing and orthotics to preserve spinal alignment, support healing, and manage pain by immobilization for approximately **8–12 weeks** (e.g., rigid collar for cervical fractures, cervical-thoracic brace for thoracic fractures, and thoracolumbar-sacral orthosis for lower back fractures).



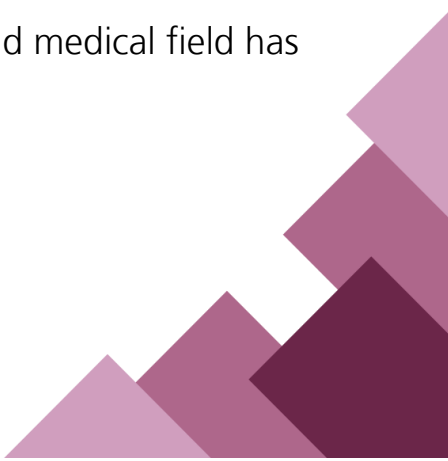
What are the vertebral injuries in the elderly?

- Over 60% of all cervical spine injuries in geriatric individuals can be attributed to accidental fall.
- Other forms of trauma include MVAs, assault, overextension and overflexion injuries.
- The physiological conditions of elderly patients such as osteoporosis and osteopenia expose them to a high risk of low energy injuries.
- Additionally, advanced age and mobility restrictions and degenerative changes also make the elderly more vulnerable to cervical spine injuries.





How to manage the vertebral injuries in the elderly?

- Treatment options for upper cervical spine injuries vary from rigid collar immobilization without reduction to halo cast immobilization with reduction, even up to surgical intervention.
 - A meta-analysis of these various strategies shows no detectable difference in morbidity, mortality, or complications but rather a very high incidence of non-union.
 - Because there could be several associated injuries, a multidisciplinary approach in trauma surgery, orthopaedics, physical therapy, and medical field has been advisable.
- 

How to manage the vertebral injuries in the elderly?

- A vertebroplasty involves immediately stabilizing a shattered spine by injecting bone cement into it.
- In situations of severe collapse and vertebral wedging, kyphoplasty—reexpansion of the fracture achieved by inserting an inflated balloon into the vertebral body and injecting bone cement—is particularly beneficial in comparison to vertebroplasty. Realigning the spine and preventing kyphotic deformity are two benefits of kyphoplasty.

Halo Immobilization with Reduction:

A brace that is used as external immobilization and protection of the cervical spine

- It is used for the stabilization of cervical spine injuries.

How to manage the vertebral injuries in the elderly?

Halo Immobilization with Reduction:

- It is commonly used when there is a need for controlled reduction of cervical spine fractures.
- This is suitable for patients who can tolerate the wearing of the halo vest and are benefiting from non-surgical management.



What are Spinal cord injuries (SCI)?

Experts classify spinal cord injuries (SCI) based on two factors: the nature of the injury's impact on the spinal cord and its location. An SCI can disrupt nerve signals traveling to and from areas below the injury site.

❖ Complete:

- Completely blocks all nerve signals, akin to shutting down all lanes of traffic.
- Typically results in permanent loss of all functions below the injury level, including paralysis.

❖ Incomplete:

- Partially disrupts nerve signals, comparable to closing only some lanes of traffic while others remain functional.
- Allows for partial preservation of functions below the injury level.

What are Spinal cord injuries (SCI)?

- ❖ The degree, severity, and extent of spinal tissue damage determine the characteristics of a traumatic brain injury. The majority of people with traumatic SCI also suffer systemic and brain damage.

What are the SCI symptoms?

✚ Acute phase (spinal shock)

Progression: soon following a traumatic brain or spinal injury, usually resolves in 48 hours

- Areflexic paralysis that is floppy
 - Tetraplegia or paraplegia (if there is damage to the cervical chord)
 - Lack of proprioceptive and polysynaptic reflexes (such as the abdominal reflex) is known as areflexia.

What are the SCI symptoms?

✚ Acute phase (spinal shock)

- Continue Areflexic paralysis that is floppy
 - breathing difficulties due to bilateral diaphragm paralysis
- **Anesthesia:** underneath the lesion's surface

✚ Acute phase (spinal shock)

- malfunction of the autonomic
- Bradycardia and hypotension in neurogenic shock
- Urine retention, bladder distention, and dribbling incontinence are examples of loss of bladder control.
- Loss of bowel control: fecal incontinence, paralytic ileus
- Priapism

What are the SCI symptoms?

Chronic phase

- Reflexes and spinal cord function eventually recover as the spinal shock subsides.
- When spinal shock resolves and certain spinal nerve pathways are spared in minor accidents, any neurological function that returns thereafter suggests an incomplete spinal cord injury (SCI).
- The continuation of significant neurological damage following spinal shock resolution in cases of full spinal cord transection suggests a complete SCI with a poor prognosis.

What are the SCI symptoms?

Complete spinal cord injury

Progression: After the spinal shock has subsided, symptoms usually appear 6–8 weeks later.

Symptoms.

- Underneath the lesion's surface.
- Bilateral loss of motor and sensory abilities, encompassing sacral segments S4–S5.
- Hypertonic muscles accompanied with spastic paralysis.
- Excessive Reflexivity.

What are the SCI symptoms?

✚ Complete spinal cord injury

- Endless clonus (such as ankle clonus).
- Breathing difficulties, coughing, and sneezing due to bilateral diaphragm.
- Paralysis.
- Lack of anal reflex.
- Reflexes pathological (positive Babinski reflex, for example).
- Malfunction of the autonomic nervous system.
- Spastic bladder: dyssynergia of the detrusor sphincter.
- Constipation/bowel impaction, fecal incontinence, diarrhoea are symptoms of neurogenic bowel.
- Impotence.



Sources and References:

ouci.dntb.gov.ua, UpToDate-com. Cleveland Clinic. Spinal Cord Injury.

American College of Surgeons, American Congress of Rehabilitation
Medicine, Best practices guidelines: Spine, Ditunno JF, Little JW, Tessler

A, Burns AS. Spinal shock revisited: a four-phase

model://www.ncbi.nlm.nih.gov/

All illustrative images from canva.com

Review and edits:

The content of this booklet has been reviewed by Neurosurgery
consultants at King Fahd University Hospital.

Neurosurgery Department
Health Awareness Unit
IAU-24-598



جامعة الإمام عبد الرحمن بن فيصل
IMAM ABDULRAHMAN BIN FAISAL UNIVERSITY

مستشفى الملك فهد الجامعي
King Fahad Hospital The University